



Archana Dubey &lt;archanadubeymzp1995@gmail.com&gt;

**Hearing Date: 05/05/2026. Please ensure that notice is served on the registered email address in compliance with the guidelines of the apex court of India.**

1 message

Archana Dubey &lt;archanadubeymzp1995@gmail.com&gt;

Mon, May 4, 2026 at 11:27 PM

To: hearingcourts8.upic@up.gov.in

Cc: webmaster-upic@up.gov.in, asp-op.mi@up.gov.in, spmzr-up@nic.in, co-city.mi@up.gov.in

## **BEFORE THE HON'BLE UTTAR PRADESH STATE INFORMATION COMMISSION, LUCKNOW**

**In the Matter of:** Archana Dubey vs PIO, Office of the Superintendent of Police, Mirzapur

**Appeal No:** A-20260400401

**Hearing Date:** 05/05/2026

### **MOST RESPECTFULLY SHOWETH:**

**1. Intentional Obstruction by PIO:** The Appellant submits that the Respondent PIO (Manish Kumar Mishra) has acted with malicious intent from the inception of this request. On 31/12/2025, the PIO arbitrarily rejected the application by mislabeling it as a "complaint letter" rather than processing it under the RTI Act, 2005.

**2. Failure of Communication:** The Appellant highlights that the PIO has **not communicated any further information or compliance** up until the date of this hearing. This persistent silence, despite the First Appellate Authority's (FAA) prior involvement, demonstrates a total disregard for the RTI Act's statutory timelines and an attempt to suppress evidence.

**3. Suppression of Criminal Evidence:** The information sought (CCTV Seizure Memos, General Diary entries, and Videography records) is critical to proving a daylight robbery involving ₹8 lakh in jewellery. By denying these records, the PIO is shielding the local police who have illegally categorised a cognizable criminal offence as a "property dispute" to avoid registering an FIR, in direct violation of the mandate in Lalita Kumari vs Govt. of UP.

**4. Contradictory Claims on Digital Records:** The Appellant maintains that a constable from Fataha Chowki performed on-site videography on 24/10/2025. The Respondents' claim that "no video was made" is a factual falsehood intended to cover the destruction of vital evidence.

**5. Personal Vulnerability:** The Appellant is currently in an advanced stage of pregnancy (approx. 36 weeks) and is displaced from her home due to the reported housebreaking. The denial of information has directly impacted her "Life and Liberty," which warrants the highest level of scrutiny by this Commission.

—

**PRAYER:**

In view of the above, the Appellant respectfully prays that this Hon'ble Commission:

- **Direct the PIO** to immediately provide free, certified copies of all 8 requested points, specifically the CCTV Seizure Memo and GD entries.

—

- **Impose a Maximum Penalty** of ₹25,000 on PIO Manish Kumar Mishra under Section 20(1) of the RTI Act for the initial malicious rejection and continued silence.

—

- **Recommend a Disciplinary Inquiry** against the PIO under Section 20(2) for obstructing justice in a serious criminal matter.

—

**Verification:** I, Archana Dubey, do hereby verify that the contents of this representation are true to the best of my knowledge.

—

**Date:** 04/05/2026

**Place:** Mirzapur (Via Online Hearing)

Archana Dubey Mobile number: 8840098979



# Rudradiagnostic Center

MISSION COMPOUND ROAD, INFRONT OF DISTRICT PANCHAYAT OFFICE,  
NEAR ICICI BANK, RAMAIPATTI, MIRZAPUR - 231001  
+91 5442-358406, 8009006803, 9936070685, 8174071224

Reported By -

**Dr. Rohan Kumar Singh**  
M.B.B.S., MD Radiodiagnosis, FIVIR

Patient Name :: MRS. ARCHANA DEVI	Age :: 28Yrs	Sex :: Female
Ref. Doctor :: Dr. SHRUTI SINGH.		Date :: 17/11/2025

## OBSTETRIC USG

Survey		Data	
FETUS	Single live	LMP	17/08/2025
PRESENTATION	Variable	GESTATIONAL AGE BY LMP	13weeks, 1days+ 0 weeks 5days
LIE	Variable	GESTATIONAL AGE BY USG	12weeks, 2days+ 0 weeks 5days
PLACENTA	Anterior grade 0	EDD/LMP	24/05/2026
-		EDD/USG	30/05/2026

### Early pregnancy NT NB SCAN Report

Single intrauterine gestation with smooth regular gestational sac.  
Yolk sac & foetal poles present.  
Cardiac activity well visualized. (FHR-152bpm)

C.R.L.: 5.49 cm corresponds to 12 wks 1days gestational age.  
BPD: 1.88cm corresponds to 12wks 6day gestational age.  
FL: 0.65cm corresponds to 12wks 0 day gestational age.  
NT: 1.1mm.

NB- visualized.(2.0mm)

Placenta : Anterior Grade-(0)

Average gestational age : 12Wks 2 days.

No evidence of subchorionic hemorrhage / collection seen.

Amniotic Fluid : Adequate .

Internal OS closed.

Cervix measured 3.7cm in length

Right Uterine PI: 0.83

Left Uterine PI: 1.08

Mean PI: 1.00

There is well defined cystic lesion of size (3.9 x 4.2cm) noted in left ovary.

#### IMPRESSION :

**SINGLE LIVE INTRAUTERINE PREGNANCY OF APPROXIMATE 12 WKS 2DAYS  
GESTATIONAL AGE WITH NORMAL NT/ NB SCAN WITH LEFT OVARIAN CYST**

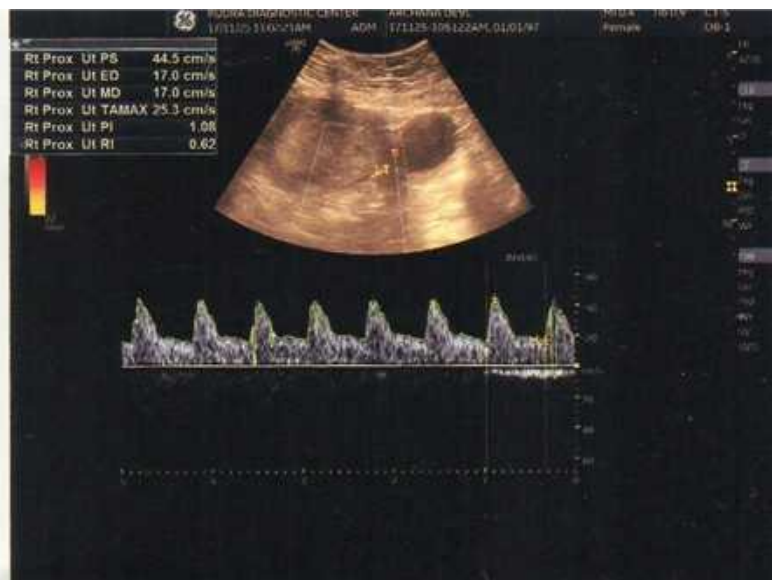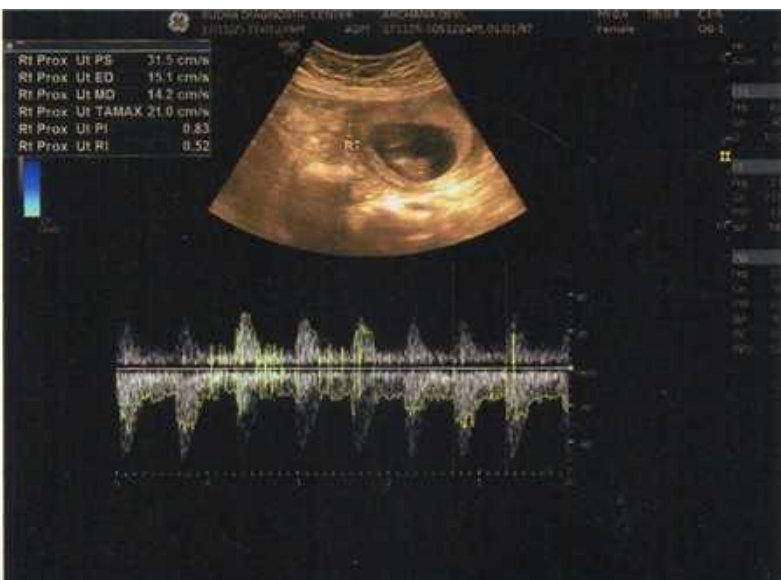**DR. ROHAN KUMAR SINGH**  
(MBBS, MD. RADIODIAGNOSIS, FIVIR)

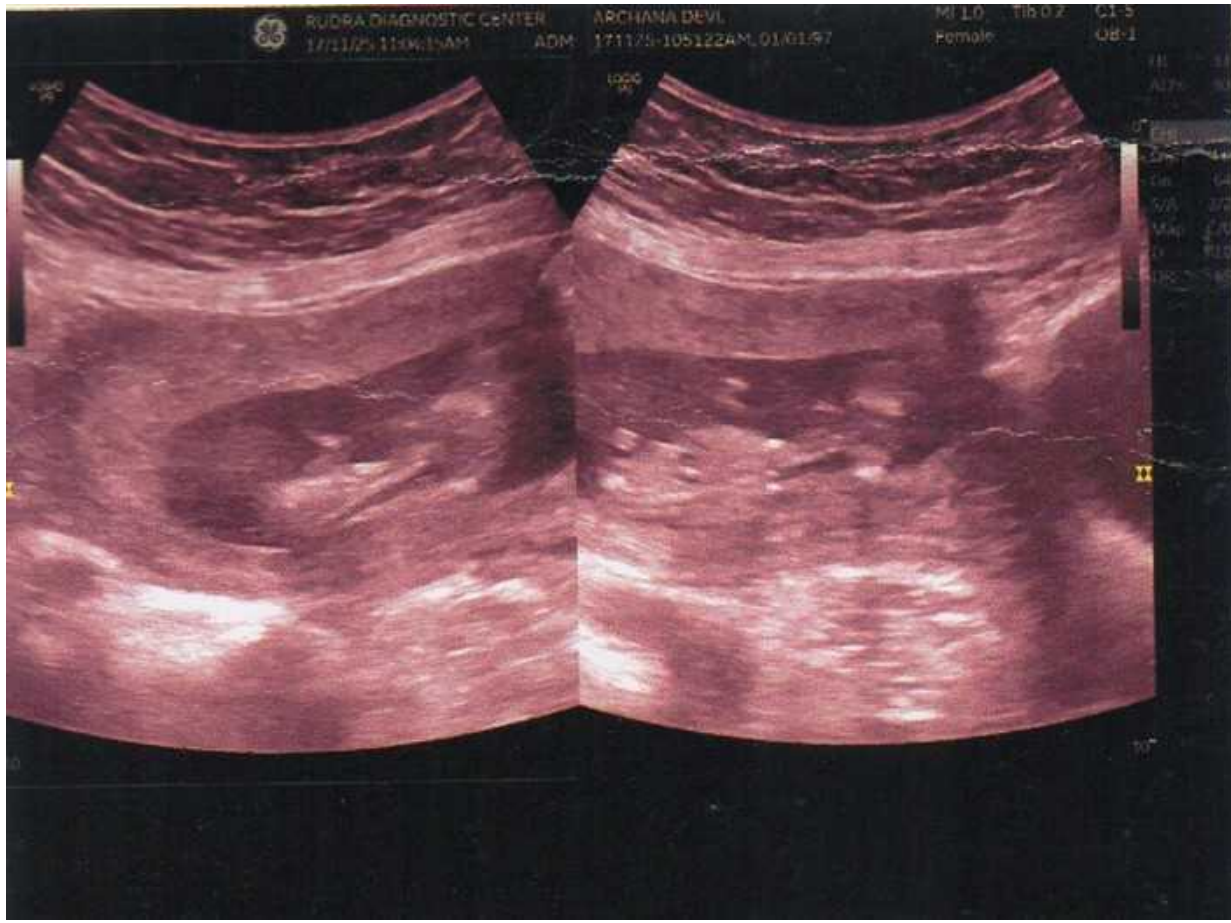
FETAL SEX DETERMINATION IS NOT DONE AND IS PUNISHABLE OFFENCE UNDER LAW

Note : This Report is for perusal of doctors only. Clinical correction is essential for final diagnosis. If test result are unsatisfactory, please contact personally.

Not for medico-legal cases.

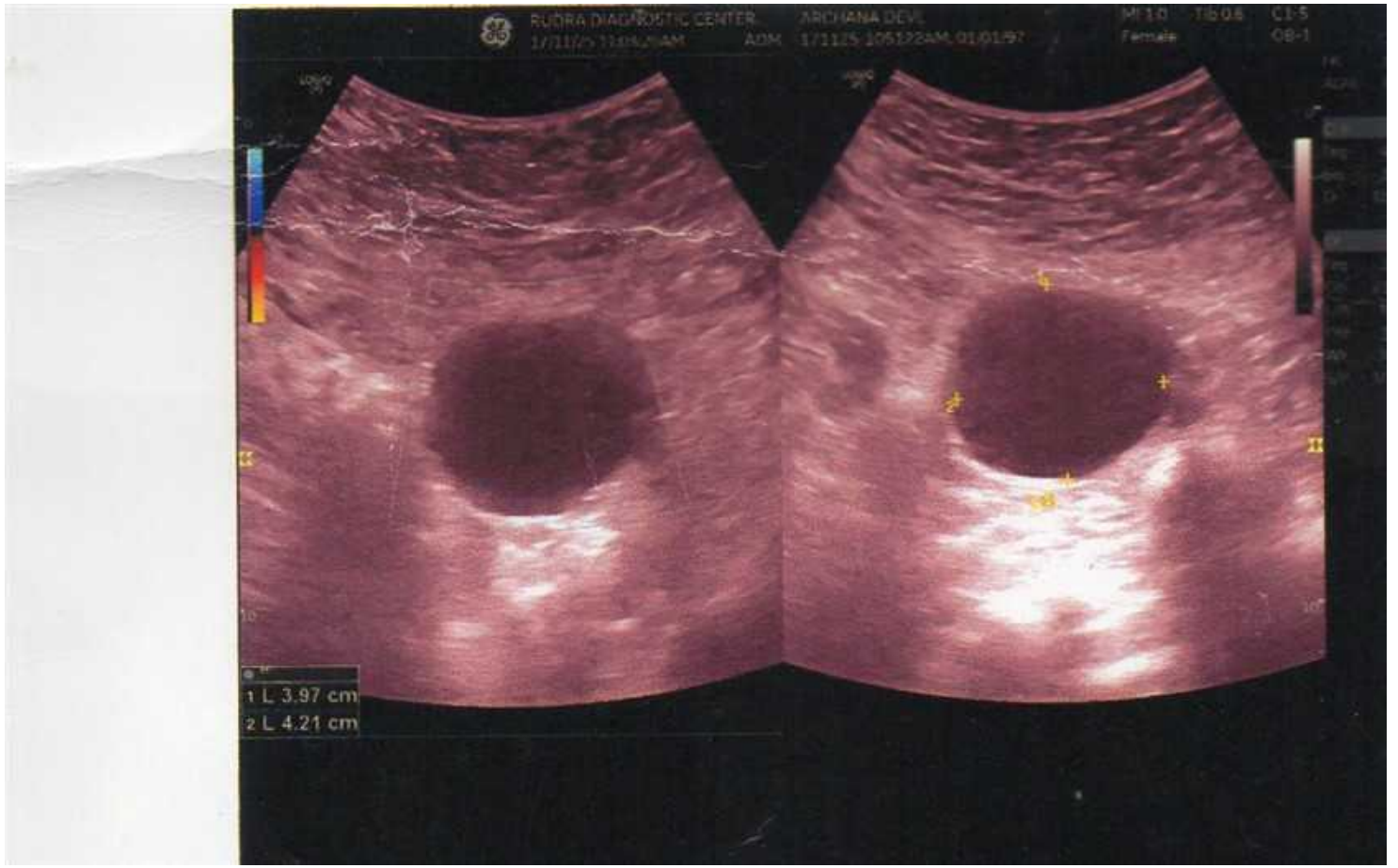
Every Day 8:00 AM to 8:00 PM

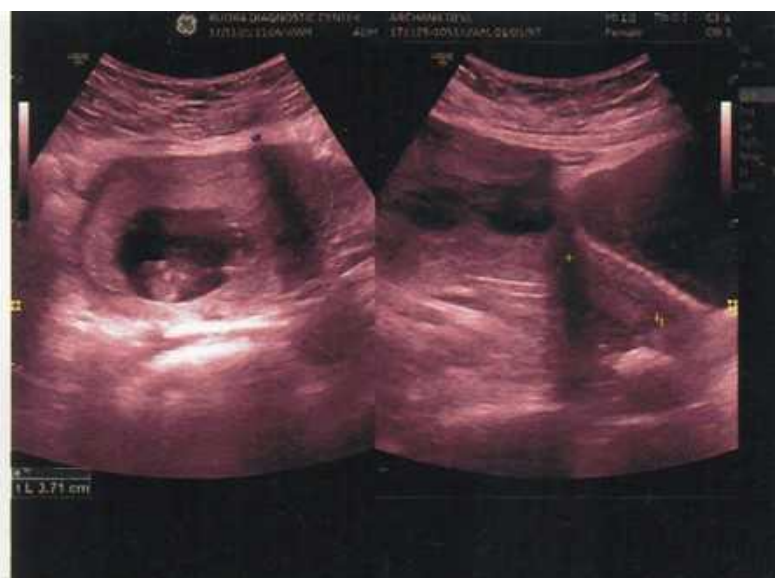
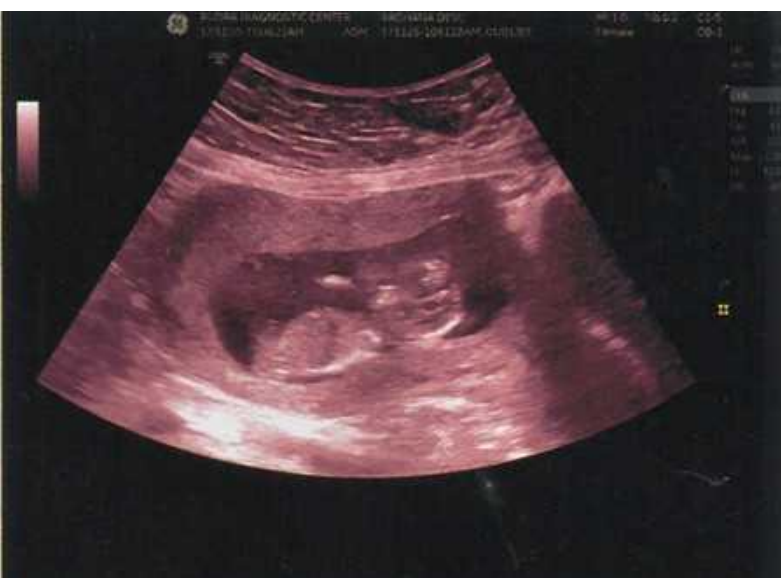


RUDRA DIAGNOSTIC CENTER ARCHANA DEVI MI L.O. Tib 02 C1.5  
17/11/25 11:06:35AM ADM: 171175-105122AM, 01/01/97 Female Q8-1









# Rudradiagnostic Center

PCPNDT/2024-25/MZP-58

MISSION COMPOUND ROAD, INFRONT OF DISTRICT PANCHAYAT OFFICE,  
NEAR ICICI BANK, RAMAIPATTI, MIRZAPUR - 231001  
+91 5442-358406, 8009006803, 9936070685, 8174071224

Reported By -

**Dr. Rohan Kumar Singh**

M.B.B.S., MD Radiodiagnosis, FIVIR

PATIENT NAME :: MRS.ARCHANA	Age /Sex ::29Yrs / F
Ref. Doctor :: Dr .SHRUTI SINGH.	Date :: 29.04.2026

## ULTRASOUND FOR FETAL WELL BEING

FETUS	Single live	LMP	17/08/2025
PRESENTATION	Cephalic	GESTATIONAL AGE BY LMP	36weeks 3days
LIE	Longitudinal	GESTATIONAL AGE BY USG	36weeks, 3days $\pm$ 1w 0 days
PLACENTA	Anterior Grade 3	EDD/LMP	24/05/2026
	Away from the os	EDD/USG	24/05/2026
LIQUOR	Adequate	APPROXIMATE FETAL WEIGHT	2922gms +/- 322.4gms
SCAR THICKNESS	~4.7mm	FHR	138BPM
CERVICAL LENGTH	3.5 cm, IOS closed		

### Findings

- Fetal movements, respiratory movements appear adequate. Fetal cardiac pulsations appear normal.
- Normal both kidneys. Urinary bladder visualized. Stomach bubble visualized.
- Situs solitus maintained. No gross intracranial abnormality. Fetal face grossly appears normal. Nasal bone visualized. Normal nuchal fold thickness.
- Fetal spine grossly appears normal. Three vessel cord seen.
- Grossly normal 4 chamber cardiac screening. Extremities grossly appear normal.
- No Cord around the neck at the time of scan.

### BIOMETRY

PARAMETERS	VALUE	AGE
HC	32.16cm	36w2d
BPD	8.93cm	36w1d
AC	32.33cm	36w2d
FL	7.18cm	36w5d

### IMPRESSION:

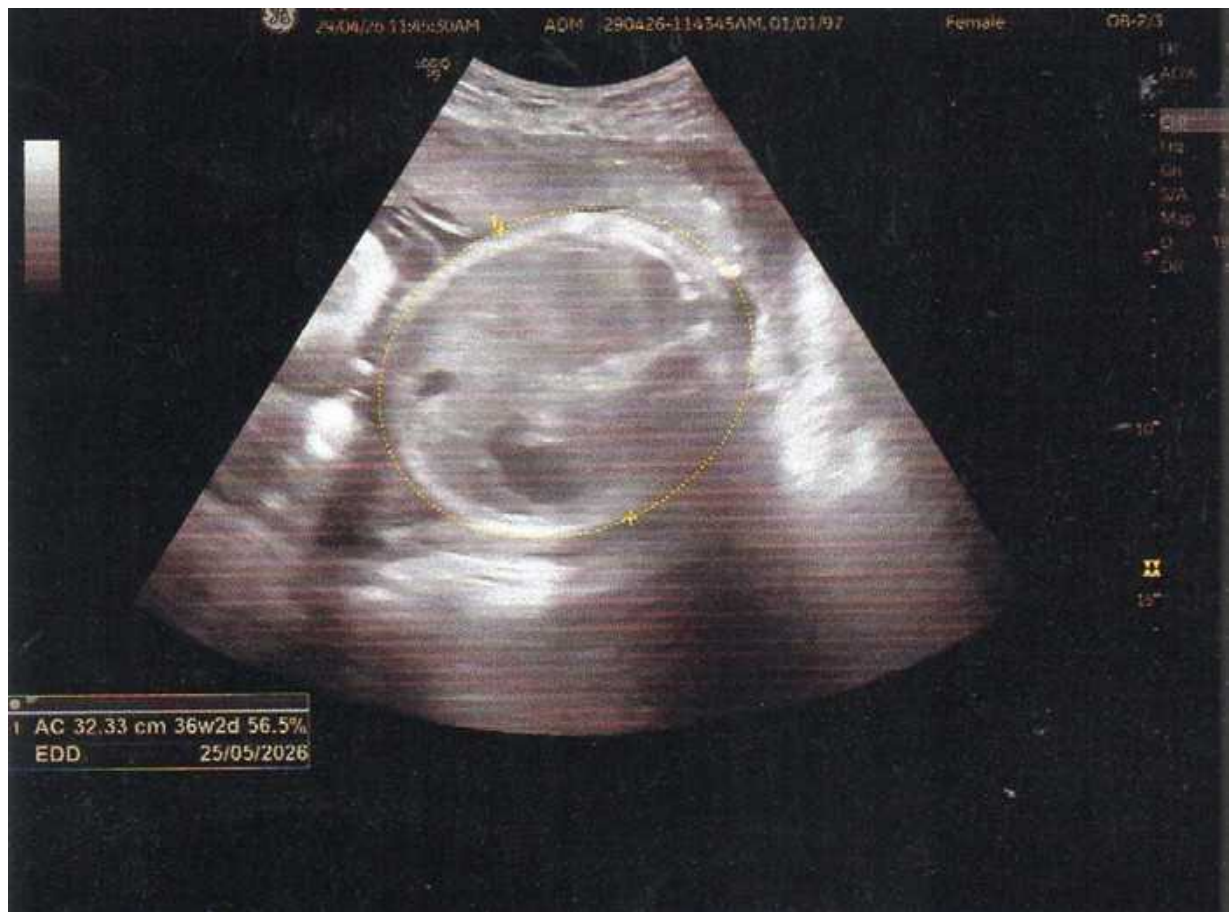- SINGLE LIVE FETUS OF MGA 36WEEKS 3DAYS
- ANTERIOR PLACENTA AWAY FROM THE OS. NO EVIDENCE OF ACCRETA, INCRETA OR PERCRETA.
- SCAR THICKNESS MEASURING ~ 4.7MM.
- ADEQUATE LIQUOR STATUS.

DR. ROHAN KUMAR SINGH  
(MBBS, MD, RADIODIAGNOSIS, FIVIR)

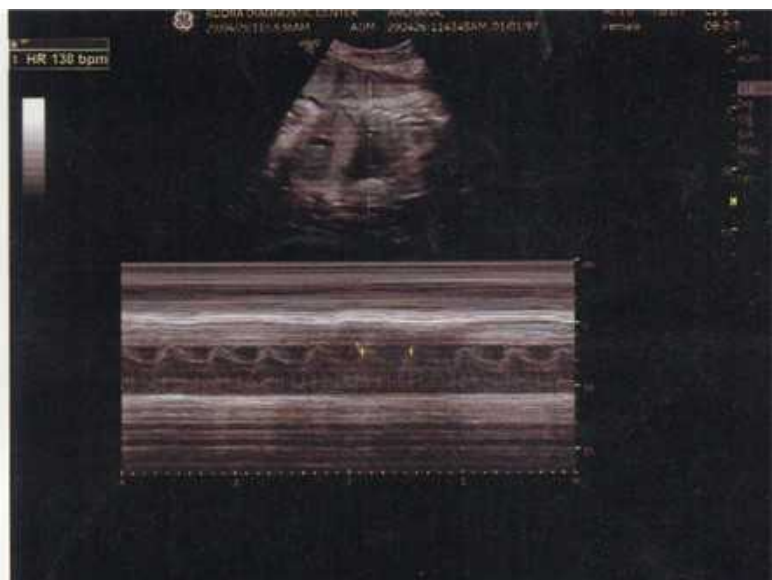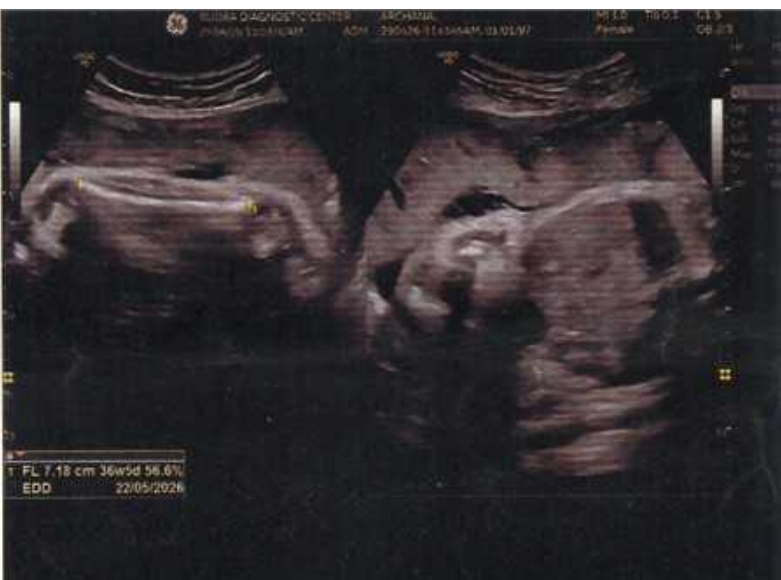Note : This Report is for perusal of doctors only. Clinical correction is essential for final diagnosis. If test result are unsatisfactory, please contact personally.

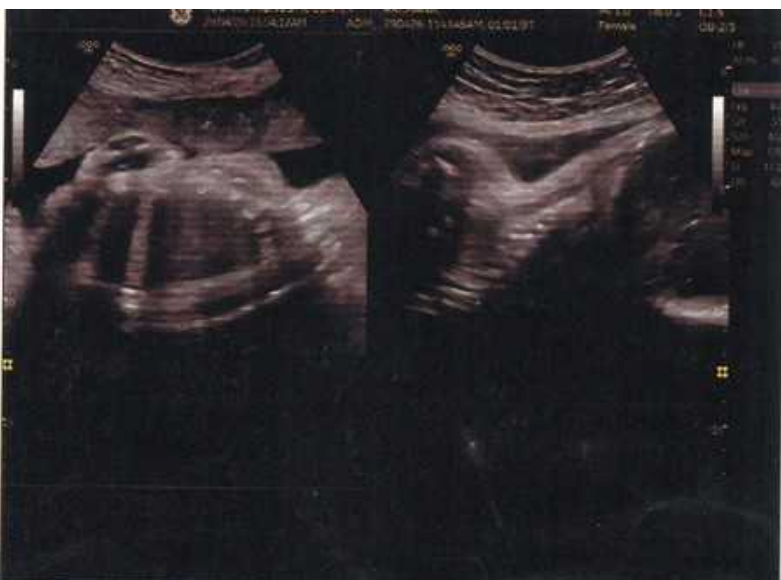Not for medico-legal cases.

Every Day 8:00 AM to 8:00 PM









RUPAK GARGA/OTIC 07/11/18  
 200426 114421AM AGH 290426 114421AM 01/01/17 Female

Sample No.	SP#	Volume (cc)	Wt	SP	Wt	SP	Wt
1	1	100	100	100	100	100	100
2	2	100	100	100	100	100	100
3	3	100	100	100	100	100	100
4	4	100	100	100	100	100	100
5	5	100	100	100	100	100	100

**Ultrasound Parameters:**  
 GA: 23.00 W 1.00 Hg  
 Biparietal: 23.00 W 1.00 Hg  
 Head Circ: 23.00 W 1.00 Hg  
 Crown Rump: 23.00 W 1.00 Hg  
 Femur: 23.00 W 1.00 Hg

**Placental Parameters:**  
 Placental Volume: 100g  
 Placental Weight: 100g  
 Placental Position: 100g  
 Placental Grade: 100g

**Amniotic Fluid Parameters:**  
 Amniotic Fluid Volume: 100g  
 Amniotic Fluid Weight: 100g  
 Amniotic Fluid Position: 100g  
 Amniotic Fluid Grade: 100g

**Other Parameters:**  
 Fetal Heart Rate: 100bpm  
 Fetal Movement: 100g  
 Fetal Tone: 100g



